

Primary fibrosarcoma of the breast: a case report

Ben Othman S(a), Chemlali M(a), Ghalleb M(a), Triki A(a), Adouni O(b) Bouzaiene H(a), Gamoudi A(b), Rahal K(a)

Oncologic surgical department(a), immuno histo cytology department(b), Salah Azaiz Institute 1006 Tunis, Tunisia

Abstract— Introduction :Breast fibrosarcoma is uncommon accounting less than 1% of all breast tumors. There are no known predisposing factors or premalignant lesions for this kind of tumor. The tumor spread via hematogenous metastasis rather than nodal one. Due to its rarity, survival rates are not defined.

Case report: We report the case of a 25-year-old girl without cancer history who had a mass of the left breast. She underwent a lumpectomy. The histological examination concluded to a primary fibrosarcoma. The medical decision was mastectomy followed by adjuvant radiotherapy and chemotherapy. The follow up until now showed no sign of local nor distant recurrence.

Conclusion: Fibrosarcoma of the breast is still one of the rare tumor. Surgical excision is the gold standard but the place of radiotherapy, chemotherapy and hormonotherapy is controversial due to the limited trials to establish the best course. Further researches have to be done.

Index Terms— Sarcoma, breast, breast cancer, fibromatosis, surgery, radiation therapy, vonricklinghausen

Introduction:

Fibrosarcoma of the breast is an uncommon mesenchymal tumor, especially in patients with no history of radiation for a prior breast carcinoma. Surgical excision is the gold standard with the aim of achieving wide negative margins. There is no large database to clearly define the role of radiotherapy, chemotherapy nor hormonotherapy.

Case report:

We report the case of a 25-year-old woman, with type 1 neurofibromatosis, who had a mass of the left breast since 6 months. Breast examination found a regular mass of 8 cm sitting in all the superior part of the breast with inflammatory skin over. No nipple abnormalities nor pathological left lymph nodes were found. The right breast and all the lymph node area were without abnormalities. The entire body was dotted by café au lait spots and several neurofibroma especially on the back and the forearms. The mammography showed a well limited dense and homogeneous opacity. The patient undertook a lumpectomy in June 2011 and the pathology examination revealed a tumor proliferation made by fusiform cells with elongated cores having

fibroblast appearance. Mitosis were very numerous and necrosis were estimated to 20% of the tumor area [fig 1]. Surgical excision limits were spaced from the tumor. In Immunohistochemical study, the tumor didn't express CD34, CD99, EMA, Keratin AE1/AE3, PS100, AML, Caldesmon, Calponin, Desmin, Myoglobin. It only expressed Vimentin and Ki 67 (60%).

These findings concluded to a high grade fibrosarcoma. A thoraco abdominal pelvic CT for staging was normal. The medical decision was mastectomy followed by adjuvant radiotherapy and chemotherapy but the patient was undisciplined and underwent only surgery in September 2011. The follow up until now is normal with no sign of local or distant recurrence.

Discussion:

Breast sarcoma is uncommon, accounting less than 1% of all breast tumors(2). Actually, the mesenchymal tissues of the organ are not as susceptible to develop neoplastic disease as the epithelial elements are. Several histological types have been described dominated by fibrosarcoma

(3). Fibrosarcomas are usually divided into two classes, depending on whether the lesion is secondary to a fibroadenoma or not. It arises like a component of malignant phyllodes tumor (4,5), or primary in the stroma which is the case of our patient (6). It has not been found specific risk factors for fibrosarcoma (5). Primary breast fibrosarcoma affects middle aged females and ages range from 17 to 86-year-old with an average age of 67 year old (1).

The wide reported presentation is a palpable painless breast mass as it's the case of our patient, but it could be painful in one third of cases (7). The size of the tumor may range from less than 1 cm to more than 4 cm (7). Both sides may be affected equivalently, the upper outer quadrant and the union of external quadrants are mostly affected (1).

There are no specific mammographic features to distinguish these forms from round breast carcinomas or non-calcified fibroadenomas.

Fibrosarcoma are often seen as a non spiculated, dense breast mass with largely indistinct borders, although some borders may be sharp [fig 3] (1).

The histological examination shows a grey tumor with infiltrative limits, variable consistency, necrosis and hemorrhage. Microscopically, cells are elongated, well limited, arranged in bundles intersecting each other at sharp angles creating thus a herringbone pattern [fig 2]. They have spindle shaped nuclei and scant cytoplasm and especially numerous mitoses with atypical ones [fig 1]. This morphological feature beside the immunohistochemical profile differentiate fibrosarcoma from other sarcomas and benign lesions such as fibromatosis, myofibroblastoma, inflammatory myofibroblastic tumor [3]. Unlike carcinoma, the histological size approximates the clinical tumor diameter. The size is not considerate as a prognosis factor (8). The histological grade and the number of mitosis are the most important prognostic factors. Metastasis to axillary lymph node are rare. The metastatic tumor spread is primarily hematogenous like all sarcomas, essentially to the lung and bone (9).

Surgical excision is the gold standard. A large excision with negative margins is required. The quality of excision conditions the prognosis. In fact, the lack of database concerning breast fibrosarcoma urges to analogize and get information from extra mammary sarcoma in another anatomical location. The Scandinavian

Sarcoma Group states, in its latest soft tissue sarcoma protocol recommendations, that an uninvolved margin of 10 mm or greater is considered sufficient. Breast conserving surgery with negative margins confers comparable survival as compared to mastectomy.

The fibrosarcoma is not lymphophilic thus a routine lymph node dissection is not recommended (10). It is only debatable in the presence of clinical nodal involvement (11). Radiation may be beneficial, always in adjuvant therapy, especially in case of an important tumor size, parietal extension or incomplete excision (12). It reduces local recurrence by using great doses (60 gray) (13). The role of chemotherapy and hormonotherapy in the management of this neoplasm has not been well studied or clearly defined. While some studies encourage using chemotherapy with aggressive combination (anthracyclin, ifosfamid, dacarbazine) advocating its significant influence on patients survival outcomes (14) others confirmed that it is not particularly efficient (15,16).

The prognosis is better than other type of sarcomas (especially angiosarcoma) but there is no survival rate related to fibrosarcoma.

Conclusion:

Fibrosarcoma of the breast is a rare entity. Total surgical resection is the mainstay of treatment. Margins status is the most important factor to affect both disease free and overall survivals. Routine axillary clearance is unnecessary. The role of radiotherapy, chemotherapy and hormonotherapy is controversial, thus careful preoperative multidisciplinary assessment is required before making the decision to treat. Further research is required to definite effective treatment strategies.

Figures:

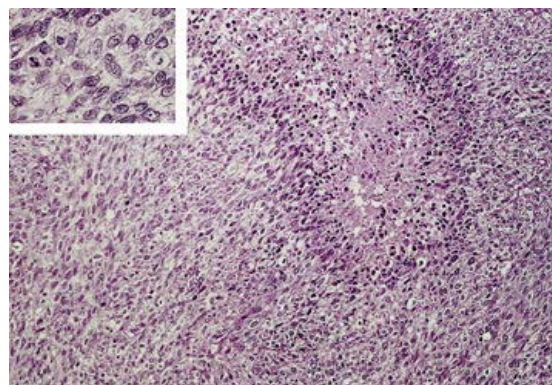


Figure1: Bundles of elongated tumors cells presenting scant cytoplasm, numerous mitosis and focal necrosis.

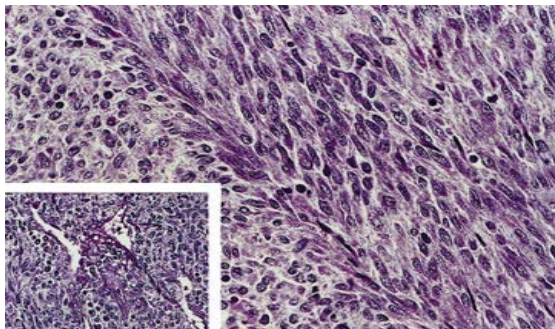


Figure 2: well limited bundles cell intersecting each other at sharp angles creating a herringbone pattern.

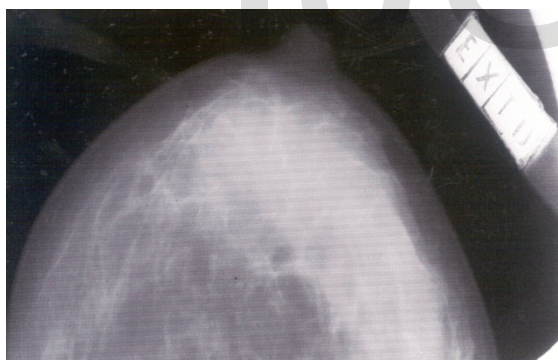

Figure 3: non-speculated, dense mass with largely indistinct borders.

References:

1. Elson BC, Ikeda DM, Andersson I, Wattsgaard C. Fibrosarcoma of the breast:

mammographic findings in five cases. *AJR Am J Roentgenol.* 1992;158(5):993–995.

2. Pollard SG, Marks PV, Temple LN, Thompson HH. Breast sarcoma. A clinicopathologic review of 25 cases. *Cancer.* 1990 Sep 1;66(5):941–4.
3. Lim SZ, Selvarajan S, Thike AA, Nasir NDBM, Tan BKT, Ong KW, et al. Breast sarcomas and malignant phyllodes tumours: comparison of clinicopathological features, treatment strategies, prognostic factors and outcomes. *Breast Cancer Res Treat.* 2016 Sep;159(2):229–44.
4. Stolnicu S, Moldovan C, Podoleanu C, Georgescu R. Mesenchymal tumors and tumor-like lesions of the breast: A contemporary approach review. *Ann Pathol.* 2015 Jan;35(1):15–31.
5. Weiner JJ, Sala AM. Fibrosarcoma of breast with metastases to axillary lymph nodes. *Am J Surg.* 1953 Sep;86(3):353–6.
6. Malard Y, de Lara CT, MacGrogan G, Bussi eres E, Avril A, Picot V, et al. Sarcomes primitifs du sein:   propos d’une s erie r trospective de 42 cas trait es   l’Institut Bergoni e sur une p riode de 32 ans. *J Gyn cologie Obst etricque Biol Reprod.* 2004;33(7):589–599.
7. Acevedo C, Amaya C, L pez-Guerra J-L. Rare breast tumors: Review of the literature. *Rep Pract Oncol Radiother.* 2014 Jul;19(4):267–74.
8. McGowan T., Cummings B., O’Sullivan B, Catton C., Miller N, Panzarella T. An analysis of 78 breast sarcoma patients without distant metastases at presentation. *Int J Radiat Oncol.* 2000 Jan;46(2):383–90.
9. Guerrero MA, Ballard BR, Grau AM. Malignant phyllodes tumor of the breast: review of the literature and case report of stromal overgrowth. *Surg Oncol.* 2003 Jul;12(1):27–37.
10. Trovik CS, Skjeldal S, Bauer H, Rydholm A, Jepsen N. Reliability of Margin Assessment after Surgery for Extremity Soft Tissue

- Sarcoma: The SSG Experience. *Sarcoma*. 2012;2012:1–5.
11. Mallebré B, Ebert A, Perez-Cantó A, Hopp H, Opri F, Weitzel H. Das Cystosarcoma phylloides der Brust. *Geburtshilfe Frauenheilkd*. 1996 Jan;56(1):35–40.
 12. Navarrete E, Janser JC, Pusel J, Rodier JF, Rodier D. [Sarcoma of the breast]. *J Chir (Paris)*. 1988 Sep;125(8–9):501–9.
 13. Chaney AW, Pollack A, McNeese MD, Zagars GK. Adjuvant radiotherapy for phyllodes tumor of breast. *Radiat Oncol Investig*. 1998;6(6):264–7.
 14. Adjuvant chemotherapy for localised resectable soft-tissue sarcoma of adults: meta-analysis of individual data. *The Lancet*. 1997 Dec;350(9092):1647–54.
 15. Silverman LR, Deligdisch L, Mandeli J, Greenspan EM. Chemotherapy for Angiosarcoma of the Breast: Case Report of 30-Year Survival and Analysis of the Literature. *Cancer Invest*. 1994 Jan;12(2):145–55.
 16. Rosen PP, Kimmel M, Ernsberger D. Mammary angiosarcoma: The prognostic significance of tumor differentiation. *Cancer*. 1988 Nov 15;62(10):2145–51.